

fluid in the bile ducts producing a higher intensity signal in comparison to the surrounding tissue. A “beaded” appearance of the bile ducts would strongly suggest PSC.

Because ERCP is invasive it can be associated with complications, including pancreatitis and bacterial cholangitis. MRCP is not invasive and is increasingly used for initial diagnosis. Recent developments in MRCP include using a contrast agent to provide better image quality. ERCP is now being reserved for therapeutic interventions, such as: extraction of bile stones, balloon dilatation of bile duct strictures, stent placement and removal, and collection of “brushings” or samples for later analysis to look for abnormal or cancerous cells. A “beaded” appearance of the bile ducts found by ERCP or MRCP would strongly suggest PSC.

Small-duct PSC is a type of PSC that affects only the small bile ducts and may show a normal cholangiogram.

#### HOW DOES A LIVER BIOPSY DETERMINE THE STAGES OF PSC?

During a liver biopsy, a hollow needle is inserted through the abdomen into the liver. Tissue samples are then taken from the needle and examined under the microscope. The characteristic sign of PSC is the appearance of concentric fibrosis (hardening) around the bile ducts, resembling an “onion” skin.

Mayo Clinic has defined the four stages of PSC this way:

Stage 1 - Fibrosis or scar tissue limited to a few spots called portal areas, little areas of “plumbing” or ductwork in the liver tissue.

Stage 2 - Fibrosis begins to appear outside the portal areas. The strands of fibrosis are not yet connected to each other.

Stage 3 - Areas of fibrosis connecting to each other.

Stage 4 - Widespread, honeycomb-like scarring (cirrhosis).

#### WHERE CAN I FIND SUPPORT AND INFORMATION?

PSC Partners Seeking a Cure is a 501(c)3 nonprofit foundation that endeavors to find a cure for primary sclerosing cholangitis.

Please consider joining our mailing list at:  
[www.pscpartners.org](http://www.pscpartners.org)

An online PSC support group was established in 1998. This is a message board (forum) on Yahoo/Health, where PSC patients and caregivers can exchange information and lend support/advice to one another:

<http://health.groups.yahoo.com/group/psc-support/>

In the United Kingdom, there is a similar group that publishes a newsletter and holds an annual meeting in Oxford with Dr. Roger Chapman, a leading PSC expert:  
[www.psc-support.demon.co.uk](http://www.psc-support.demon.co.uk)

There is also a parents’ support group, especially helpful for parents of young children, as PSC presents itself differently in pediatric patients, and is treated accordingly.

This group is found at:

<http://health.groups.yahoo.com/group/pscmoms/>

For post-transplant PSC patients, there is a support group with discussions based on the special needs of being post-surgical, immunosuppressed, and their “at-risk” status. You may join this group at:

<http://health.groups.yahoo.com/group/Livertx-PSC/>

To join a global group of PSCers and caregivers for social connection, education and sharing, check out Facebook at:

<http://tinyurl.com/pscpartnersfacebook>

To find other PSC Facebook groups, click on the info tab at the above address.

For information on:  
our local/regional support groups  
our free quarterly newsletter  
our annual conference for PSC patients and caregivers  
our other brochures:  
[www.pscpartners.org](http://www.pscpartners.org)

A PSC Literature web site was developed in 2004 to provide PSC patients and caregivers easy access to a vast body of information concerning PSC and allied illnesses:

[www.psc-literature.org](http://www.psc-literature.org)

For detailed information on inflammatory bowel disease, please visit the Crohn’s and Colitis Foundation of America (CCFA) web site at:

[www.cffa.org](http://www.cffa.org)

#### FOR MORE INFORMATION, OR TO HELP FUND THE CURE:

Visit our website at:  
[www.pscpartners.org](http://www.pscpartners.org)

or contact Ricky Safer by e-mail at:  
[Contactus@pscpartners.org](mailto:Contactus@pscpartners.org)

or send a tax-deductible donation to:  
PSC Partners Seeking a Cure  
5237 S. Kenton Way  
Englewood, CO 80111

To order more brochures, please write to us at:  
[Brochures@pscpartners.org](mailto:Brochures@pscpartners.org)

diagnosing  
**PSC**  
primary sclerosing cholangitis

*This brochure was written by persons without formal medical training. The information in this brochure is not intended nor implied to be a substitute for professional medical advice, diagnosis, or treatment. Please consult with your doctor before using any information presented here. The views and opinions expressed herein are not intended to endorse any product or procedure.*

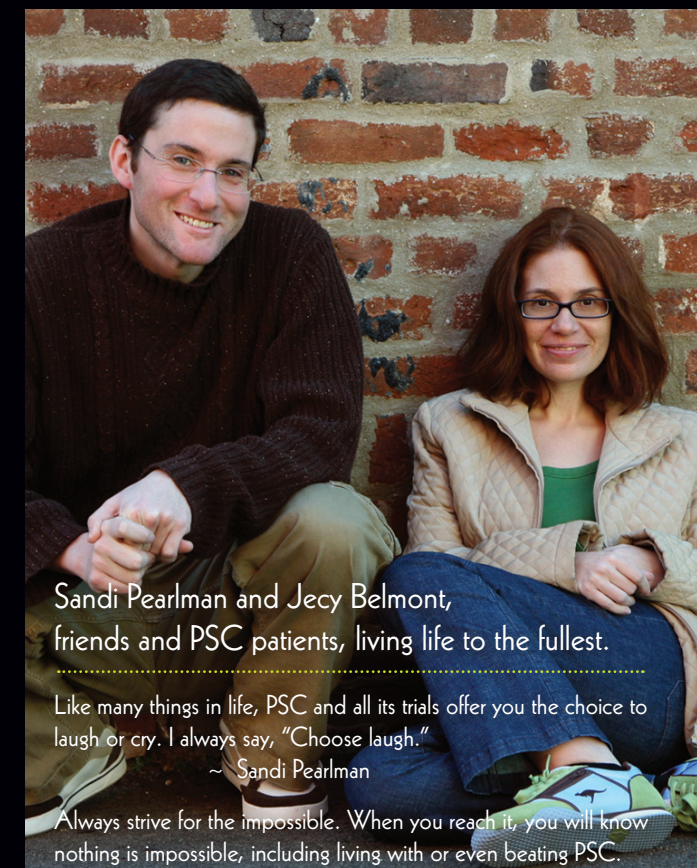
PHOTO CREDIT:

[Karen.Pearlman@www.Kpearlmanphotography.com](mailto:Karen.Pearlman@www.Kpearlmanphotography.com)

 PSC PARTNERS  
SEEKING A CURE

diagnosing  
**PSC**  
primary sclerosing cholangitis

 PSC PARTNERS  
SEEKING A CURE



Sandi Pearlman and Jecy Belmont, friends and PSC patients, living life to the fullest.

Like many things in life, PSC and all its trials offer you the choice to laugh or cry. I always say, “Choose laugh.”

~ Sandi Pearlman

Always strive for the impossible. When you reach it, you will know nothing is impossible, including living with or even beating PSC.

~ Jecy Belmont

A Publication of  Partners Seeking a Cure

## WHAT IS PSC?

Primary Sclerosing Cholangitis (PSC) is a chronic disease of the bile ducts both inside and outside the liver. The ducts become narrowed and can cause cirrhosis (scarring), which can lead to liver failure. PSC is thought to be an autoimmune disease. The diagnosis of PSC is usually based on a combination of imaging techniques and liver function blood tests. (Please refer to our online brochure, "Living with PSC," at <http://www.pscpartners.org/pdfs/PSCBrochure.pdf> for further information.)

## WHAT ARE COMMON SYMPTOMS OF PSC?

Many patients with PSC are asymptomatic. Symptoms, when they occur, may include:

- Intense itching (pruritus) - particularly on hands or feet, though it can occur anywhere, including in eyes and mouth.
- Fatigue - feeling run down, unable to get enough sleep, flu-like tiredness.
- Pain - in right side or middle of abdomen towards rib cage; often termed right upper-quadrant (RUQ) pain. Pain may be of any intensity, last for an indefinite period, and extend to the shoulder blade.
- Jaundice - yellowing of eyes and skin caused by excess bilirubin that the liver cannot process. May be accompanied by dark urine and light-colored bowel movements.
- Chills and fever - signs of bacterial infections in bile ducts requiring immediate medical attention including administering antibiotics.

## WHAT OTHER DISEASES ARE ASSOCIATED WITH PSC?

PSC is often found in people who have inflammatory bowel disease (IBD)—primarily ulcerative colitis (UC), and sometimes Crohn's disease. Research shows that roughly 75 percent of PSC patients will develop IBD. PSC might be found before IBD, or vice versa. The form of IBD in PSC may be mild or even "silent;" that is, it may not show obvious

symptoms such as abdominal pain or bloody stools. It is critical that your doctor test for IBD because early treatment with medications can bring IBD quickly under control.

As many as 25 percent of patients with ulcerative colitis have related problems, such as inflammation of the joints, skin, or eyes.

Continued inflammation of the bowel is a risk factor for developing colon cancer. Routine screening for colon cancer (by colonoscopy) is recommended.

Celiac disease, sometimes associated with PSC, damages the villi in the small intestine and interferes with absorption of food nutrients. People with celiac disease cannot tolerate certain wheat proteins. A diagnosis is made through a biopsy or blood test.

PSC may be associated with other autoimmune diseases, including thyroid disease, arthritis, iritis, skin disorders, and lung disorders.

There are mainly two types of cancer that occur with increased frequency in PSC patients: colon cancer and bile duct cancer (cholangiocarcinoma). The increased risk in colon cancer is mainly in PSC patients who also have underlying IBD. Frequent screening with colonoscopy is recommended. All PSC patients are at greater risk for cholangiocarcinoma, irrespective of bowel disease. Risk factors are poorly identified, although smoking seems to increase the PSCer's risk. Cholangiocarcinoma may be difficult to diagnose. Despite MRI, CT, serum cancer markers, and ERCP, many remain undiagnosed until the very late stages of tumor growth. Cholangiocarcinoma may be treated by resection or transplantation; but often the tumor is too advanced when diagnosed to consider these options. Palliative procedures include RFA (radio frequency ablation) of liver tumors, chemoembolization of the hepatic tumor, or chemotherapy.

## WHAT BLOOD TESTS ARE ABNORMAL IN PSC?

PSC may be suspected in patients who have no symptoms, but who, through routine blood tests (liver function tests) have elevated serum liver enzyme levels. These enzymes include:

- alanine aminotransferase (ALT),
- aspartate aminotransferase (AST),
- alkaline phosphatase (ALP), and
- gamma-glutamyltranspeptidase (GGT).

Elevated ALT and AST generally indicate liver cell damage. Elevated serum ALP and GGT usually indicate a cholestatic liver disease or bile duct blockage. Your doctor may also screen for serum albumin, serum bilirubin, and blood clotting function (prothrombin time and/or international normalized ratio (INR)). Serum albumin may be decreased, and INR increased with more advanced stage of the disease. Elevated serum bilirubin may correlate with jaundice (yellowing of the skin).

Although these tests may be abnormal, they are nonspecific and may be abnormal in liver disease from any cause. Other, more specific testing is required to confirm the diagnosis of PSC.

## WHAT ROLE DO ANTIBODIES PLAY IN DIAGNOSIS?

PSC overlaps pathophysiologically with autoimmune hepatitis—for this reason, some patients with PSC will test positive for certain autoantibodies, ANA, and ASMA. Once again, the latter tests are nonspecific and other diseases may need to be ruled out. PSC is commonly, but not always, associated with atypical p-ANCA (perinuclear-antineutrophil cytoplasmic) antibodies.

## MY DOCTOR RECOMMENDED COLONOSCOPY—WHY?

PSC is commonly associated with inflammatory bowel disease, either ulcerative colitis or Crohn's disease. Colonoscopy is useful for examining the lining of the bowel to determine the presence or

absence of inflammatory bowel disease. In addition, patients who have both PSC and inflammatory bowel disease may be at particularly high risk for colon cancer; colonoscopy is the most sensitive and specific test for detecting colon cancer.

Colonoscopy is the visual examination of the large intestine (colon) using a lighted, flexible fiber optic or video endoscope, which shows images on a computer monitor. The endoscope allows other instruments to be passed through in order to perform biopsies, remove polyps, or inject solutions. Preparation for the procedure involves drinking a solution that flushes the colon clean, or taking laxatives and enemas.

The patient is mildly sedated; the endoscope is inserted through the rectum and moved gently around the bends of the colon. The procedure typically takes 30 minutes and is usually done on an outpatient basis. There is minimal pain from the procedure.

## WHAT IS ERCP OR MRCP AND WHY ARE THEY ORDERED?

If your doctor suspects PSC due to liver function tests and an antibody profile, imaging the bile ducts is essential. The gall bladder and liver may initially be viewed by ultrasound. Two imaging techniques are now extensively used for viewing the bile ducts: endoscopic retrograde cholangiopancreatography (ERCP), and magnetic resonance cholangiopancreatography (MRCP). Both are outpatient procedures.

In ERCP, a flexible tube, or endoscope, is inserted into the mouth, esophagus, stomach, and bile ducts. The patient is sedated and there is minimal pain. A dye is injected into the bile and pancreatic ducts. An X-ray is then taken to show the bile and pancreatic ducts.

In MRCP, often no contrast dye is used, no radiation is involved, and no endoscope is employed. Rather, patients are simply exposed to a strong magnetic field and the bile ducts are visualized due to the